
HARRIS COUNTY ARCHIVES

Document Separation Sheet

The following material has been removed from:

Box: 1483
Folder: 33
Location:

Description of materials:

Accession No: 2008.027

Date: n.d.

Reason for removal:

Closed - Photo Skeletal Remains ML 73-3378 William R. Lawrence

New Location:

Box: 1484

Folder: 13

Location:

Notes:

Make 2 copies: place one in new location with transferred materials,
one in original location.

Date: 7/21/2010

Signed: 

Sam Rayburn
LOCATION: San Augustine Co

GRAVE # 1

UNKNOWN # 22

M.E. CASE # 73-3378

IDENTIFIED

NAME: _____

STILL UNKNOWN

I N V E N T O R Y S H E E T

HAIR SAMPLES: _____

AUTOPSY REPORT: ROUGH FINAL

BODY X-RAYS: HCME _____ OTHER _____

SUPPLEMENTAL: ROUGH FINAL

DENTAL X-RAYS: HCME _____ OTHER _____

INVESTIGATORS REPORT: ROUGH FINAL

HCME PHOTOS: BODY _____ PERSONAL EFFECTS _____

SUPPLEMENTAL: ROUGH FINAL

CLOTHING _____ DENTAL _____

TOXICOLOGY REPORT

PHOTO FROM FAMILY: _____

DENTAL EXAMINATION: ROUGH FINAL FORM

MISSING PERSONS REPORT _____

POINTS OF COMPARISON: ROUGH FINAL FORM

DEATH CERTIFICATE _____

HCME DENTAL CHART _____

BRIEF PHYSICAL DESCRIPTION _____ ✓

OTHER DENTAL CHART _____

SYNOPSIS OF MEDICAL TESTIMONY: _____

EVIDENCE SHEET: _____

CORRESPONDENCE: _____

COMPARISONS: ① Larry Battin - no match 11-20-74

② Paul Woodall - no match 11-13-73

③ David Wayne Waggoner - no match dental 6-6-86

④ Larry Russel Ebert - no match by dental 4-2-87
(PB+CW)

OTHER: Burial transit permit

Dr. Jack Pruitt's autopsy report.

Sam Rayburn
LOCATION: San Augustine Co

GRAVE # 1

UNKNOWN # 22

M.E. CASE # 73-3378

IDENTIFIED

NAME: _____

STILL UNKNOWN

I N V E N T O R Y S H E E T

HAIR SAMPLES: _____

AUTOPSY REPORT: ROUGH FINAL

BODY X-RAYS: HCME _____ OTHER _____

SUPPLEMENTAL: ROUGH FINAL

DENTAL X-RAYS: HCME _____ OTHER _____

INVESTIGATORS REPORT: ROUGH FINAL

HCME PHOTOS: BODY _____ PERSONAL EFFECTS _____

SUPPLEMENTAL: ROUGH FINAL

CLOTHING _____ DENTAL _____

TOXICOLOGY REPORT

PHOTO FROM FAMILY: _____

DENTAL EXAMINATION: ROUGH FINAL FORM

MISSING PERSONS REPORT _____

POINTS OF COMPARISON: ROUGH FINAL FORM

DEATH CERTIFICATE _____

HCME DENTAL CHART _____

BRIEF PHYSICAL DESCRIPTION _____ ✓

OTHER DENTAL CHART _____

SYNOPSIS OF MEDICAL TESTIMONY: _____

EVIDENCE SHEET: _____

CORRESPONDENCE: _____

COMPARISONS: ① Larry Battin - no match 11-20-74

② Paul Woodall - no match 11-13-73

③ David Wayne Waggoner - no match dental 6-6-86

④ Larry Russel Ebert - no match by dental 4-2-87
(PB+CW)

OTHER: Burial transit permit

Dr. Jack Pruitt's autopsy report.

JACK PRUITT, M. D.

P. O. BOX 160

LUFKIN, TEXAS 75901

PATHOLOGY

June 18, 1974

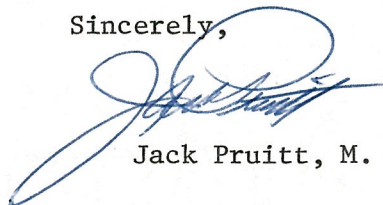
Am
27

Dr. Joseph A. Jachimczyk
209 Court House Building
Houston, Texas 77001

Dear Joe:

Enclosed is all of the tissue that I have left from the body of Billy Lawrence, the first of my series of four examined in San Augustine last August tenth, and the only one that did not come through your office. Don Lambright, Harris County Assistant District Attorney, asked that I send it to you for toxicologic analysis that you could testify to it in San Antonio next month. Many thanks.

Sincerely,



Jack Pruitt, M. D.

JP:ss
encl tissue

PRUITT MEDICAL LABORATORIES

P. O. BOX 160

LUFKIN, TEXAS 75901

HO 27

301 NORTH BYNUM
(713) 634-4451

JACK PRUITT, M. D.
RAUL M. GUTIERREZ, M. D.

AUTOPSY REPORT

(Series No. 20) *(NOT IN HO SERIES)*

Name: Body No. 1, identified as William Ray Lawrence
Date of Autopsy: August 10, 1973, 12:30 p.m.
Place of Autopsy: Wyman Roberts Funeral Home, San Augustine, Texas
Authority: San Augustine County, Texas Justice of the Peace C. A. Renfroe #1
Autopsy Prosector: Jack Pruitt, M. D.

CIRCUMSTANCES: Body found buried near Broadus, Texas, on the afternoon of Thursday August 9, 1973.

GROSS EXAMINATION: The unclothed body is fully wrapped in a thick transparent plastic sheet and tied with several lengths of thick cord resembling venetian blind cord about 1/8 inch in diameter. The body is that of a slender white adolescent male 68 inches in length, the weight not estimated. The scalp hair is light brown and straight, about shoulder length, 12 - 15 inches. The wrists are secured behind the body with fabric adhesive tape. The legs are similarly taped together just above the ankles. Anoose of thick cord like that described around the original plastic wrapping is secured around the neck, typical of a "hangman's noose", with a loose end 12 inches long extending down the back. The tissues of the neck are compressed, and indicate that this was applied tightly before death.

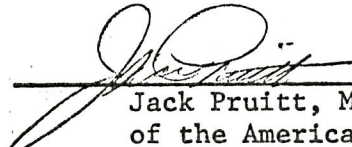
The skin is essentially intact over the entire body, although very slippery and having advanced postmortem decomposition, and there is no evidence of any penetrating wound. The outer skin surfaces over the fingers and toes have sloughed away, and make fingerprint identification impossible, according to two Texas Department of Public Safety Investigators present at the scene. The facial features can be recognized, although the nose has advanced decomposition, the bones intact, no recognizable evidence of trauma. Two teeth are out of their sockets, numbers 1 and 8 as indicated on the accompanying dental chart, postmortem in character, apparently all 32 teeth having erupted and having no evidence of decay or filling (see dental chart for description). The penis, scrotum and anus are intact, without evidence of mutilation, the pubic hair intact and recognizable.

The heart, lungs, and abdominal organs are shrunken and pasty, virtually unrecognizable, but without evidence of severe antemortem trauma.

According to information supplied by the father and the dentist, as well as a photograph published in the Houston Post, this body was identified as that of William Ray Lawrence, 15-year-old white boy. The condition of the body is consistent with a postmortem interval of approximately one month.

MICROSCOPIC EXAMINATION: Microscopic examination of the solid organs is of no value because of the severe postmortem decomposition of the tissues.

PATHOLOGIC DIAGNOSIS AND CAUSE OF DEATH: Death by strangulation, postmortem interval of about one month.


Jack Pruitt, M. D., Diplomate
of the American Board of Pathology

Original to Judge Renfroe
Xerox copy to Sheriff Hoyt
Xerox copy retained for files

Case #1 San Augustine 8-10-73

N-73-54

(Ident. as William Ray Lawrence)

NAME _____ DATE _____ AGE _____

1	2	3	4	5	6	7	8	9	10	11	12	13	14	15	16	
32	31	30	29	28	27	26	25	24	23	22	21	20	19	18	17	

FORM 1429 COLWELL CO., CHAMPAIGN, ILL.

all teeth apparently in, but #1 out post-mortem, found in pharynx, no trauma; #8 out post-mortem, not found, no trauma - socket smooth, resembles #9. #9 (left upper medial incisor) larger & more prominent than others, small "chip" mesial tip, which if matched with absent #8 would form a notch. No recognized cavities, no fillings.

Other characteristics for identification:

1. Height 5'8", slender, weight not estimated.
2. Long straight brown hair, about shoulder length, est. 12-15 inches in longest portion.
3. Eyes apparently blue, but marked post-mortem decomposition.
4. Features resemble photo Waxton Post Sun. 8-12-73

**JOSEPH A. JACHIMCZYK FORENSIC CENTER
OF HARRIS COUNTY
AUTOPSY EVIDENCE SUBMISSION/REQUEST FORM**

ML/OC # <u>73-3378</u>	Law Enforcement Agency: Agency #:
Evidence Del. By Dr. <u>Victor Forney</u>	Police Investigator Assigned to Case: Name:
Rec'd. in Laboratory by:	Address: <u>HCME</u>
Date: <u>12.17.2001</u> Time: <u>405</u> am/pm <input checked="" type="radio"/>	Direct Telephone # () _____ - _____

EVIDENCE LISTING

Item(s) Requested	Item(s) Received in Laboratory
<u>2 ribs</u> <u>2 bones from distal Extremities</u>	

Nature of Death:	Date of Death:
Decedent:	Race _____ Sex _____ Age _____

Received by: _____ Date: _____ from H.C.M.E.

Signature _____
Print Name _____

Released by: _____ Date: _____

Signature _____
Print Name _____

Note: Since per HOME files show this decedent as unknown, + no record of body being buried, the remains are here/HOME

Full Body Here

1973 MASS MURDER INVENTORY CASES TO DATE AS OF 071501

DR. DELATTRE VIEWED CASE:

CASE FINDINGS...SEE ATTACHED REPORT DATED

ITEM #	CASE #	DECEDENT'S NAME	TYPE OF REMAINS	*LOCATION OF REMAINS	DATE FOUND	DATE ID'D & BY	WHAT METHOD
* (22)	73-3378	per HOME Records Unknown #22	Skull	Invest. Locker Room #4	8-9-73	Dr. Pruitt #110	via dental compensation
	see 73-3378(A)	W-m-15-18 yr			Sam Raburn		+ see Dr. Stinson
FOUND@:		per Dr. Pruitt's records William Ray Lawrence			Nude/Decomp		exam @ autopsy
NOK NOTIFIED:	(Y/N)	W-m-15					
DATE / TIME NOTIFIED:		per Dr. Pruitt's records				Dr. Pruitt	
AUTOPSY DONE BY/DATE:		See "Other Info" below					
INVESTIGATOR REPORT:	(Y/N)	AUTOPSY REPORT:	(Y/N)	POLICE REPORT:	(Y/N)	SCENE PHOTOS:	(Y/N)
DEATH CERTIFICATE:	(Y/N)	DATE D/C SIGNED:	NOT IN FILE				
		San Augustine Co., J. P. Renfro					
FULL BODY XRAYS:	(Y/N)	DENTAL CHART/XRAYS:	(Y/N)	DNA:	(Y/N)	RELEASE SIGNED:	(Y/N)
@ autopsy - HOME		(X) color photo (jaw) + charting in file		5-2-95 TOOTH to lobby		DATE:	Not in file
BY:						BY:	
TRANSFERRED TO HCME							
BY:	INFO NOT IN FILE						
FUNERAL HOME:	Wyman Roberts	BURIED	permit dated 8-11-73	CREMATED			
MANNER OF DEATH:	Asphyxia due to strangulation					DOD:	
SOURCE:	HOME Records + Investigator File						
OTHER INFORMATION:	Autopsy #1 (73-3378A) done by Dr. Pruitt @ Wyman Roberts FH 8/10/73						
	+ Autopsy #2 done @ HOME by Dr. Sachinczyk 8-15-73						
	6-9-93 FBI letter, 1-17-95 OPS letter						
	See Comp. cases 73-3376, 3377					NO Property prints on file @ HOME	

Has wrong ME# on form

PRUITT MEDICAL LABORATORIES

P. O. BOX 160

LUFKIN, TEXAS 75901

301 NORTH BYNUM
(713) 634-4451

JACK PRUITT, M. D.
RAUL M. GUTIERREZ, M. D.

AUTOPSY REPORT

(Series No. 20) (NOT IN HO SERIES)

Name: Body No. 1, identified as William Ray Lawrence
Date of Autopsy: August 10, 1973, 12:30 p.m.
Place of Autopsy: Wyman Roberts Funeral Home, San Augustine, Texas
Authority: San Augustine County, Texas Justice of the Peace C. A. Renfroe #1
Autopsy Prosector: Jack Pruitt, M. D.

CIRCUMSTANCES: Body found buried near Broaddus, Texas, on the afternoon of Thursday August 9, 1973.

GROSS EXAMINATION: The unclothed body is fully wrapped in a thick transparent plastic sheet and tied with several lengths of thick cord resembling venetian blind cord about 1/8 inch in diameter. The body is that of a slender white adolescent male 68 inches in length, the weight not estimated. The scalp hair is light brown and straight, about shoulder length, 12 - 15 inches. The wrists are secured behind the body with fabric adhesive tape. The legs are similarly taped together just above the ankles. A noose of thick cord like that described around the original plastic wrapping is secured around the neck, typical of a "hangman's noose", with a loose end 12 inches long extending down the back. The tissues of the neck are compressed, and indicate that this was applied tightly before death.


The skin is essentially intact over the entire body, although very slippery and having advanced postmortem decomposition, and there is no evidence of any penetrating wound. The outer skin surfaces over the fingers and toes have sloughed away, and make fingerprint identification impossible, according to two Texas Department of Public Safety Investigators present at the scene. The facial features can be recognized, although the nose has advanced decomposition, the bones intact, no recognizable evidence of trauma. Two teeth are out of their sockets, numbers 1 and 8 as indicated on the accompanying dental chart, postmortem in character, apparently all 32 teeth having erupted and having no evidence of decay or filling (see dental chart for description). The penis, scrotum and anus are intact, without evidence of mutilation, the pubic hair intact and recognizable.

The heart, lungs, and abdominal organs are shrunken and pasty, virtually unrecognizable, but without evidence of severe antemortem trauma.

According to information supplied by the father and the dentist, as well as a photograph published in the Houston Post, this body was identified as that of William Ray Lawrence, 15-year-old white boy. The condition of the body is consistent with a postmortem interval of approximately one month.

MICROSCOPIC EXAMINATION: Microscopic examination of the solid organs is of no value because of the severe postmortem decomposition of the tissues.

PATHOLOGIC DIAGNOSIS AND CAUSE OF DEATH: Death by strangulation, postmortem interval of about one month.


Jack Pruitt, M. D., Diplomate
of the American Board of Pathology

Original to Judge Renfroe
Xerox copy to Sheriff Hoyt
Xerox copy retained for files

Case #1 San Augustine 8-10-73

N-73-54

(Ident. as William Ray Lawrence)

NAME																DATE		AGE									
1	2	3	4	5	6	7	8	9	10	11	12	13	14	15	16												

FORM 1429 COLWELL CO., CHAMPAIGN, ILL.

all teeth apparently in, but #1 out post-mortem, found in pharynx, no trauma; #8 out post-mortem, not found, no trauma - socket smooth, resembles #9. #9 (left upper medial incisor) larger + more prominent than others, small "chip" mesial tip, which if matched with absent #8 would form a notch. No recognized cavities, no fillings.

Other characteristics for identification:

1. Height 5'8", slender, weight not estimated.
2. Long straight brown hair, about shoulder length, est. 12-15 inches in longest portion.
3. Eyes apparently blue, but masked post mortem decomposition.
4. Features resemble photo *New York Post Sun* 8-12-73

Note: Since per HOME files show this decedent as unknown
 + no record of body being buried, the remains are here/HOME

(Full Body Here)

1973 MASS MURDER INVENTORY CASES TO DATE AS OF 071501

DR. DELATRE VIEWED CASE:

CASE FINDINGS...SEE ATTACHED REPORT DATED

ITEM #	CASE #	DECEDENT'S NAME	TYPE OF REMAINS	*LOCATION OF REMAINS	DATE FOUND	DATE ID'D & BY	WHAT METHOD
--------	--------	-----------------	-----------------	----------------------	------------	----------------	-------------

(22)	73-3378	Per Home Records Unknown #22	Skull	Invest.	8-9-73	Dr. Pruitt #110	
	See 73-3378(A)	W-m-15-18 yr		Locker	Sam Raburn		via dental comparison
		(Per Dr. Pruitt's records William Ray Lawrence		Box #4	Skeletal		+ see Dr. Stinson Nude/Decomp exam @ autopsy

FOUND@:

NOK NOTIFIED: Y / N

DATE / TIME NOTIFIED: per Dr. Pruitt's records NOTIFIED BY WHOM: Dr. Pruitt

AUTOPSY DONE BY/DATE: See "Other Info" below

INVESTIGATOR REPORT: Y / N AUTOPSY REPORT: Y / N POLICE REPORT: Y / N SCENE PHOTOS: Y / N

DEATH CERTIFICATE: Y / N DATE D/C SIGNED: NOT IN FILE

San Augustine Co., J. P. Kenfro

FULL BODY XRAYS: <input checked="" type="checkbox"/> Y / <input type="checkbox"/> N	DENTAL CHART/XRAYS: <input checked="" type="checkbox"/> Y / <input type="checkbox"/> N	DNA: <input checked="" type="checkbox"/> Y / <input type="checkbox"/> N	RELEASE SIGNED: <input type="checkbox"/> Y / <input checked="" type="checkbox"/> N
@ Autopsy - HOME	(X) color photo (jaw) + charting in file	5-2-95 TOOTH to lobby	DATE: Not in file BY:

TRANSFERRED TO HCME

BY: INFO NOT IN FILE

FUNERAL HOME: Wynman Roberts BURIED permit dated 8-11-73 CREMATED

MANNER OF DEATH: Asphyxia due to strangulation DOD:

SOURCE: HOME Records + Investigator File

OTHER INFORMATION: Autopsy #1 (73-3378A) done by Dr. Pruitt @ Wynman Roberts FH 8/10/73
 + Autopsy #2 done @ HOME by Dr. Sachimezyk 8-15-73
 6-9-93 FBI letter, 1-17-95 OPS letter
 See Comp. cases 73-3376, 3377 NO Property, prints on file @ HOME

Has wrong info on form

OFFICE OF THE MEDICAL EXAMINER
OF HARRIS COUNTY

HARRIS COUNTY COURT HOUSE
HOUSTON, TEXAS 77002

AUTOPSY REPORT

Case 73 - 3378

August 15, 1973

PATHOLOGICAL DIAGNOSIS ON THE BODY


OF

Unknown #22

Asphyxia due to strangulation.

OPINION

It is our opinion that the decedent,
Unknown #22, came to his death as a
result of asphyxia due to strangulation -
Homicide.



Joseph A. Jachimczyk, M.D., J.D.
Chief Medical Examiner

(See Companion Cases 73 - 3376 and 73 - 3377)

POSTMORTEM EXAMINATION ON THE BODY OF

UNKNOWN #22

HISTORY: This unidentified white male body was found at approximately the same time that three other bodies were uncovered during the evening of August 9, 1973, near Lake Sam Rayburn in San Augustine County, Texas. One was identified as William Ray Lawrence. His body was not sent to the Harris County Morgue. The remaining three were sent to this morgue. (73-3376, 73-3377 and 73-3378.) The three bodies arrived at the Harris County Morgue at 1:00 p.m. on August 11, 1973.

AUTOPSY: The autopsy was performed by Chief Medical Examiner Joseph A. Jachimczyk, M.D., assisted by Assistant Medical Examiners Ethel E. Erickson, M.D., and G. Sheldon Green, M.D., and Dr. Paul G. Stimson, beginning at 10:15 a.m. on August 15, 1973, in the Harris County Morgue.

EXTERNAL APPEARANCE: The decomposing body was that of a young Caucasian male, measuring approximately 68 inches in length and weighing a residual 75 pounds, submitted in a crashbag. The body was covered with white embalmer's preservative powder. The head was covered with fairly short dark brown hair, measuring up to 3-1/2 inches in length. The body had been previously autopsied. There were no clothes.

Complete postmortem X-rays of the body did not reveal the presence of any radiopaque objects.

INTERNAL EXAMINATION: Section: The body was opened through the previously made Y-shaped prior autopsy incision. The abdominal and thoracic viscera were re-examined. The body cavities emitted an unpleasant aroma.

HEART: The heart was decomposing.

LUNGS: The lungs together weighed 450 grams. They were collapsed and decomposing.

LIVER: The liver weighed 450 grams. The liver was mostly autolyzed. The gallbladder was empty.

Pancreas and Adrenals: The pancreas and adrenals were autolyzed.

SPLEEN: The spleen weighed 50 grams. There was postmortem decomposition.

GENITOURINARY TRACT: The kidneys together weighed 50 grams. They were autolyzed.

GASTROINTESTINAL TRACT: Most of the intestines were eaten away with lime. The stomach was empty.

BONES: There was a complete postmortem separation of the vertebral column between the 1st and 2nd lumbar vertebrae. The left femur was disarticulated from its acetabulum. A good portion of the soft tissue was absent. There was post-mortem absence over the right and left elbows. The distal epiphysis of the left ulna was not fused.

NECK: The hyoid bone was intact. There was hemorrhage into the tissue surrounding the hyoid bone. There was periesophageal hemorrhage. There was hemorrhagic discoloration of the larynx and first portion of the trachea on the inner surface. The thyroid cartilage was intact, but there was hemorrhage around the thyroid cartilage.

HEAD: The scalp was reflected in the usual coronal fashion. The calvarium was not remarkable. There were no skull fractures. The brain was mushy. The residual brain weighed 750 grams.

Following the autopsy, a second set of X-rays was made in order to attempt to determine the skeletal age of this individual.

The first film was an anteroposterior view of the chest and shoulders and included most of both humeri. The spine was intact. The ribs were intact. Both clavicles were visible. There was no evidence of a medial clavicular epiphysis. Most of both scapulae could be seen. The proximal humerus epiphyses were not fused. A distinct epiphyseal plate was visible in both. None of the anular epiphyses of the vertebral column appeared to be fused.

A film of the pelvis showed considerable rotation. Portions of both forearms and hands were visible. Technical detail of the latter was good, while the pelvis was underpenetrated. The distal epiphyses of the right radius was well defined. It was not fused, and there was a distinct epiphyseal plate.

The distal portion of the left radius was also well defined and also showed no fusion. In the pelvis, only the anterior portions of the iliac crest epiphyses were well visualized. These showed a distinct epiphyseal plate and appeared not to be fused. The proximal ends of the femurs were barely visible and could not be evaluated. Two of the left metacarpals were quite well demonstrated. Both appeared to have completely fused epiphyses.


Film of the knees showed a well defined epiphyseal plate in the distal femurs. Fusion, if any, was very early. The proximal tibial epiphyses were less well visualized, but there were cortical defects at the margins of the epiphyseal plates and these appeared not to be fused. The fibulae were not well visualized.

The fourth X-ray showed the feet and ankles in the dorsal plantar view. The distal ends of the long bones of the legs were not well visualized. The metatarsal epiphyses all appeared to be completely fused. The epiphyseal lines were present in several of the proximal phalanges. They were most clearly defined in the proximal phalanges of the great toes, particularly at the proximal ends. These appeared to be unfused or only partially fused, as there was some suggestion of cortical defect at the margins of the epiphyseal plates.

Based upon the X-ray criteria, the age was estimated to be approximately 15 to 18 years.

DENTAL EXAMINATION

Utilizing the Universal System, all of the third molars are partially erupted. The upper left central, number 9, and the upper left lateral, number 10, are avulsed. The upper right second bicuspid, number 4, has undergone a 180 degree rotation. The buccial and lingual cusps are reversed. Number 22 is in mesial labial rotation. Number 25 is in lingual version, blocked out by tooth 24 and 26. Number 26 is in mesial labial rotation and number 27 is in mesial labial rotation. Jaw relationships are normal. The peridontal condition is average. Caries are noted as follows: the upper right second molar, number 2, has distal and occlusal pit caries. The upper right first molar, number 3, has distal and occlusal pit caries. There is occlusal caries on the upper left first bicuspid, number 12, on the upper left second bicuspid, number 13, on the occlusal and distal occlusal pits on the upper left first molar, which is tooth 14. Caries is present on the occlusal and distal pits on the upper left second molar, which is tooth 15, on the lower left second molar, occlusal caries, which is tooth 18. On the occlusal on the lower left second bicuspid, which is tooth 20, occlusal caries, on the lower right first bicuspid, which is tooth 28, and on the lower right second bicuspid, which is tooth 29, and an occlusal caries on the lower right second molar, which is tooth 31.



Paul G. Stimson, D.D.S., M.S.

Autopsy

INVESTIGATOR'S REPORT

Investigator: H. C. Gregory.

~~XXXX~~

Case No. 74 - 3378

Decedent: _____ Race _____ Sex _____ Age _____

Address: _____

Death: FOUND August 10, 1973 Approx. Time 7:00 ~~P.M.~~ A.M.

Place of Death: 2-1/2 miles south of Broaddus, Texas, off F.M. 3185, San Augustine County, Texas

Place of Inquest: _____

Date and Time of Inquest: _____ A.M.
P.M.

Location, Position, and Surroundings of Body:

The decedent was lying face upward in a grave.

Clothing: The decedent was nude.

Information: San Augustine County Sheriff's Department, San Augustine County, Texas, Deputy Sheriff Richard Davis furnished the following information on August 11, 1973, at the Harris County Morgue, Houston, Texas.

The decedent identified as "Unknown #22" was found about 7:00 a.m. on August 10, 1973, when Elmer Wayne Henley (suspect in this case) led San Augustine County Sheriff's Department, Sheriff John Hoyt to a gravesite located about 5-4 feet from the gravesite of William Ray Lawrence, near the above location. Henley identified the gravesite by several crossed sticks on top of the ground. He specifically remembered this gravesite inasmuch as he returned subsequent to the original burial of the decedent and found that something had dug into the ground about the gravesite. Henley then placed a masonite board over the hole and covered the board with a thin layer of earth under which there was a lime substance, under which there was a masonite board, under which was the hole in which the decedent was placed, rolled into a plastic covering and taped shut with silver colored air conditioning tape. Decomposition was advanced, according to the Deputy Sheriff. Scene photographs were taken by Department of Public Safety, Austin, Texas. The decedent was taken to Wyman Roberts Funeral Home in St. Augustine, Texas, on August 10, 1973, by Dr. Jack Pruitt of Lufkin, Texas. The diagnosis was strangulation. Deputy Davis said that Henley made the (over)

Property: There was no property involved.

Transferred to Morgue by:

Funeral Home Conducting Service:

H. C. Gregory

#27
FD-118

HOUSTON POLICE DEPARTMENT MISSING PERSON REPORT											
RECEIVED BY Head		DATE AND TIME RECEIVED 8-9-73 10:15 AM		<input checked="" type="checkbox"/> ADULT <input checked="" type="checkbox"/> JUVENILE		<input type="checkbox"/> MISSING <input type="checkbox"/> RUNAWAY		<input type="checkbox"/> LOST			
PLACE AND TIME MISSING PERSON LEFT HOME 1st Week in June		RESIDENCE ADDRESS 310 W. 31st				M.P.B. NO.		J.O. NO.			
ISSUING PERSON'S NAME LAWRENCE, WILLIAM RAY				LOCATION LAST SEEN		FO <input checked="" type="checkbox"/>		RE. <input type="checkbox"/>			
LAST OR MOTHER NAME				NICKNAME							
DESCRIPTION OF MISSING PERSON		SEX M	DESCENT W	AGE 15	HEIGHT 5'7"	WEIGHT 135 lbs	HAIR Brown	EYES Blue	BUILD 	COMPLEX. 	
IDENTIFYING MARKS AND CHARACTERISTICS											
OTHERS WORN (NAME OF GARMENT - COLOR - DESCRIPTION) (INCLUDE DESCRIPTION OF JEWELRY AND LUGGAGE CARRIED)											
UNK.											
PLACE - DATE - TIME PERSON LOCATED						LOCATED BY (PERSON OR AGENCY)					
BIRTH PLACE Houston		BIRTH DATE 3-14-53		MARITAL STATUS (MARRIED - SINGLE - DIVORCED) Single		MENTAL CONDITION (GOOD - POOR - ETC.) Good					
OCCUPATION		RELIGION		SCHOOL (NAME & LOCATION)		GRADE					
POSSIBLE CAUSE OF ABSENCE				PROBABLE DESTINATION		FORMER ADDRESS OF MISSING PERSON					
PERSONAL HABITS (INV., DRINKER, GAMBLER)		REPORTED MISSING BEFORE		DATE		WHERE LOCATED ON PRIOR OCCASION					
		<input type="checkbox"/> YES <input type="checkbox"/> NO									
VEHICLE DRIVEN (YEAR - MAKE - BODY TYPE - COLOR(S)) - LICENSE NUMBER - IDENTIFYING CHARACTERISTICS											
PERSON LAST SEEN MISSING PERSON		RESIDENCE ADDRESS				PHONE		RELATIONSHIP			
PERSON REPORTING ABSENCE TO POLICE Shirley A. Lane		RESIDENCE ADDRESS 818 Byron				PHONE 852-6746		RELATIONSHIP Aunt			
PARENTS OR GUARDIANS (JUVENILE ONLY) Horace Lawrence		RESIDENCE ADDRESS 310 W. 31st				PHONE 862-9947		RELATIONSHIP Father			
RELATIVES AND FRIENDS		RESIDENCE ADDRESS				PHONE		RELATIONSHIP			
VEHICLE NO.						MESSAGE CONC. BY		DATE & TIME			

It is stated that the...

...

THIS REPORT FOR REFERENCE & ELIMINATION PURPOSES ONLY
INVESTIGATOR'S REPORT

Autopsy View Case No. DID NOT COME TO 7286 Investigator: Gregory
Decedent: WILLIAM RAY LAWRENCE Race W Sex M Age 15
Address: 310 West 31st St., Houston
Death: FOUND 8-9-73 Approx. Time 8:00PM A.M.
Place of Death: 2 1/2 miles South of Broadus, Texas off FM-3185, St. Augustine County
Place of Inquest: _____
Date and Time of Inquest: _____ A.M.
P.M.
Location, Position, and Surroundings of Body: SEE BELOW

Clothing: NAKED- Face up in grave

Information: St. Augustine County Dep. Sheriff RICHARD DAVIS furnished the following info. on 8-11-73 at 7286.

St. Augustine County Sheriff JOHN HOYT, Box 61, St. Augustine, Texas, was directed to a gravesite near the above location by WAYNE HENLEY (suspect in the above case) on 8-9-73 about 8:00PM. HENLEY identified the gravesite as being at a point where 4 sticks were crossed on the ground. Beneath the crossed sticks was a thin layer of earth beneath which there was a plyboard. Beneath the plyboard was a hole in the ground into which had been placed a substance similar to lime, along with a plastic covering, securely taped, containing the body of the decedent. The decedent's body had been rolled in the plastic covering, but none of the lime substance was within the plastic covering. A cord tied in a "hangman's noose" was around the neck of the decedent. His ankles were bound together with silver colored ~~xxx~~ air conditioning tape. His wrists were taped behind his back with similar tape. The grave was about 18"-19" in depth and there were two cinderblocks in the grave.

Photos were taken at the scene by D. P. S., Austin.
An autopsy was performed at the Wyman Roberts FH, St. Augustine, Texas on 8-10-73 by Dr. JACK FRUITT of Lufkin, Texas. DX: STRANGULATION.

DEP. DAVIS SAID THAT HENLEY MADE THE STATEMENT THAT ONE OF THE "UNKNOWN #20, #21 OR #22 COULD BE A BOY NAMED "GARCIA."
The cord found around the decedent's ~~xxxx~~ neck was tagged at 7286 under Property: NONE) the name WILLIAM RAY LAWRENCE.

Transferred to Morgue by: SUBSEQUENT TO THE AUTOPSY IN ST. AUGUSTINE THE BODY OF THE DECEDENT WAS RELEASED BY ST. AUGUSTINE COUNTY AUTHORITIES TO FOREST PARK FH. Funeral Home Conducting Service: Forest Park FH

PRUITT MEDICAL LABORATORIES
P. O. BOX 180
LUFKIN, TEXAS 75901

301 NORTH BYNUM
(713) 334-4431

AUTOPSY REPORT

JACK PRUITT, M. D.
RAUL M. GUTIERREZ, M. D.

(Series No. 20) *(Not in Ho series)*
Name: Body No. 1, identified as William Ray Lawrence
Date of Autopsy: August 10, 1973, 12:30 p.m.
Place of Autopsy: Wyman Roberts Funeral Home, San Augustine, Texas
Authority: San Augustine County, Texas Justice of the Peace C. A. Renfroe #1
Autopsy Prosecutor: Jack Pruitt, M. D.

CIRCUMSTANCES: Body found buried near Broaddus, Texas, on the afternoon of Thursday August 9, 1973.

GROSS EXAMINATION: The unclothed body is fully wrapped in a thick transparent plastic sheet and tied with several lengths of thick cord resembling venetian blind cord about 1/8 inch in diameter. The body is that of a slender white adolescent male 68 inches in length, the weight not estimated. The scalp hair is light brown and straight, about shoulder length, 12 - 15 inches. The wrists are secured behind the body with fabric adhesive tape. The legs are similarly taped together just above the ankles. A noose of thick cord like that described around the original plastic wrapping is secured around the neck, typical of a "hangman's noose", with a loose end 12 inches long extending down the back. The tissues of the neck are compressed, and indicate that this was applied tightly before death.

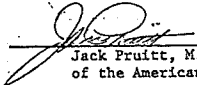
The skin is essentially intact over the entire body, although very slippery and having advanced postmortem decomposition, and there is no evidence of any penetrating wound. The outer skin surfaces over the fingers and toes have sloughed away, and make fingerprint identification impossible, according to two Texas Department of Public Safety Investigators present at the scene. The facial features can be recognized, although the nose has advanced decomposition, the bones intact, no recognizable evidence of trauma. Two teeth are out of their sockets, numbers 1 and 8 as indicated on the accompanying dental chart, postmortem in character, apparently all 32 teeth having erupted and having no evidence of decay or filling (see dental chart for description). The penis, scrotum and anus are intact, without evidence of mutilation, the pubic hair intact and recognizable.

The heart, lungs, and abdominal organs are shrunken and pasty, virtually unrecognizable, but without evidence of severe antemortem trauma.

According to information supplied by the father and the dentist, as well as a photograph published in the Houston Post, this body was identified as that of William Ray Lawrence, 15-year-old white boy. The condition of the body is consistent with a postmortem interval of approximately one month.

MICROSCOPIC EXAMINATION: Microscopic examination of the solid organs is of no value because of the severe postmortem decomposition of the tissues.

PATHOLOGIC DIAGNOSIS AND CAUSE OF DEATH: Death by strangulation, postmortem interval of about one month.


Jack Pruitt, M.D., Diplomate
of the American Board of Pathology

Original to Judge Renfroe
Xerox copy to Sheriff Hoyt
Xerox copy retained for files

Case #1 San Augustin 8-10-73

N-73-54

(Ident. as Williams Ray Lawrence)

NAME																DATE																AGE																																																																			
1	2	3	4	5	6	7	8	9	10	11	12	13	14	15	16	17	18	19	20	21	22	23	24	25	26	27	28	29	30	31	32	33	34	35	36	37	38	39	40	41	42	43	44	45	46	47	48	49	50	51	52	53	54	55	56	57	58	59	60	61	62	63	64	65	66	67	68	69	70	71	72	73	74	75	76	77	78	79	80	81	82	83	84	85	86	87	88	89	90	91	92	93	94	95	96	97	98	99	100
[Dental drawing of upper teeth]																[Dental drawing of lower teeth]																[Dental drawing of upper teeth]																																																																			
[Dental drawing of lower teeth]																[Dental drawing of upper teeth]																[Dental drawing of lower teeth]																																																																			
FORM 1428 COLWELL CO., CHAMPAIGN, ILL.																																																																																																			

all teeth apparently in, but #1 out post-mortem, found in pharynx, no trauma; #8 out post-mortem, not found, no trauma. — socket smooth, resembles #9. #9 (left upper medial incisor) larger & more prominent than others, small "chip" mesial tip, which if matched with absent #8 would form a notch. No recognized cavities, no fillings.

Other characteristics for identification:

1. Height 5'8", slender, weight not estimated.
2. Long straight brown hair, about shoulder length, est. 12-15 inches in longest portion.
3. Eyes apparently blue, but marked post mortem decomposition.
4. Features resemble photo *Haunted Post* Sem. 8-12-73

N-73-54

Return X-ray

W.L. George, D.D.S.
 1920 Ashland
 Houston, Tex 77008

NAME <i>Lawrence, Billy</i>		DATE <i>6-30-71</i>	AGE <i>13</i>								
ADDRESS <i>310 W. 31st</i>		PHONE <i>862-9947</i>									
CHARGE TO _____ ADDRESS _____											
DATE	TOOTH	SERVICE NUMBER	CHARGE	PAID	BALANCE						
<i>6-30-71</i>		<i>Always #9, 10 - X-ray - N Cul + Dep. to Dr. Robert Kunk</i>	<i>N/A</i>								

FORM 1420 COLWELL CO., CHAMPAIGN, ILL.

I referred this patient over to Dr. B.J. Kunk. I doubt if he ever went to his office, because I never received any follow-up X-rays from his office concerning endodontic treatment.

W. George, D.D.S.

Received by _____ DATE _____



OFFICE OF THE MEDICAL EXAMINER OF HARRIS COUNTY
JOSEPH A. JACHIMCZYK FORENSIC CENTER
1885 OLD SPANISH TRAIL
HOUSTON, TEXAS 77054

January 17, 1995

Texas Department of Public Safety
Crime Laboratory
Danny Carter, Latent Prints
P. O. Box 4143
Austin, Texas 78765

Reference: 1973 Mass Murders; ML#73-3378
Unknown white male

Attached is the single print obtained from the unknown white male that I spoke with you about this date. This is the only print we were able to obtain so after your search could you please return it to us.

Thank you for your assistance in this matter.

Sincerely,

A handwritten signature in cursive script, appearing to read "Pat Banks".

Pat Banks
Investigator

LEAVE BLANK

TYPE OR PRINT ALL INFORMATION IN BLACK

FBI LEAVE BLANK

LAST NAME NAM FIRST NAME MIDDLE NAME

UNIDENTIFIED DECEDENT

STATE USAGE

ALIASES

CONTRIBUTOR

TX101023M

CO MED EXAM
HOUSTON, TX

SIGNATURE OF PERSON FINGERPRINTED

DATE OF BIRTH DOB

Month Day Year

THIS DATA MAY BE COMPUTERIZED IN LOCAL STATE AND NATIONAL FILES

DATE ARRESTED OR RECEIVED DOA

SEX

RACE

HGT

WGT

EYES

HAIR

PLACE OF BIRTH POB

DATE

SIGNATURE OF OFFICIAL TAKING FINGERPRINTS

Found 8-9-73

M

W

5'5 1/2"

5'9"

bro

est. 18/22

YOUR NO OCA

73-3378

LEAVE BLANK

CHARGE

Unidentified skeletal remains

FBI NO. FBI

CLASS

SID NO. SID


REF

FINAL DISPOSITION

SOCIAL SECURITY NO. SOC

NCIC CLASS - FPC

CAUTIONS

6. Left Thumb	7. Left Index	8. Left Middle	9. Left Ring	10. Left Little
				#10 

5-25-93 THE ABOVE INKED IMPRESSIONS OF FINGER # 10 WERE TAKEN FROM SKELETAL REMAINS RECOVERED FROM A MASS GRAVE IN 1973. THIS INDIVIDUAL HAD PROBABLY BEEN DEAD A YEAR OR SO WHEN THE BODY WAS RECOVERED ALONG WITH 23 OTHERS. THIS IS THE ONLY AND THE BEST FINGERPRINT AVAILABLE. IF ITS CONDITION IS SUCH AS NOT TO BE USABLE WE HAVE NO RECOURSE.

6 L THUMB

7 L INDEX

8 L MIDDLE

9 L RING

10 L LITTLE


 CECIL WINGO, CHIEF INVESTIGATOR
 HARRIS COUNTY MEDICAL EXAMINER

FBI
 NOTE: ~~THIS IS OUR ONLY FINGERPRINT~~
~~THE~~ AFIS DOES NOT INCLUDE
 FINGER # 10

THIS IS OUR ONLY
 FINGERPRINT.

LEFT FOUR FINGERS TAKEN SIMULTANEOUSLY

L. THUMB

R. THUMB

RIGHT FOUR FINGERS TAKEN SIMULTANEOUSLY



Washington, D.C. 20537

Date: 6-9-93

Contributor:

The enclosed fingerprints and/or correspondence are being returned to you because of the reason(s) indicated below:

- (Contributor) (Registration) (Service) number omitted.
- Incomplete descriptive data.
- Indicate correct sex of subject.
- Name (not shown at top of card) (name and signature differ).
- Date of birth (not given) (not clear) (incomplete). If unknown, give approximate age.
- Charge and/or date of arrest not given.
- Inked finger impressions not on card.
- Advise reason for submission of fingerprints; if criminal, furnish charge; or, if applicant, furnish position for which applying.
- FBI number omitted. Rolled impressions of all ten fingers, plus plain impressions, must be submitted if FBI number not available.
- Advise if subject is deceased.
- Furnish final disposition.
- Impressions not black on standard white fingerprint card stock.
- Apparently mailed to us by mistake.
- Our records fail to reveal a statute from your state requiring fingerprinting for the position indicated on the enclosed card(s).
- There is no indication the enclosed cards and/or correspondence have been processed through your state identification bureau of central agency prior to submission to the FBI.
- Enclosed card may have been submitted by your office. Please list contributor, and return to FBI. If not submitted by your office, please advise.
- We do not include information unsupported by fingerprints in our files.
- Finger impressions on attached card are identical with those on file for subject of attached record; however, the description data on the card evidently pertains to another individual.
- Descriptive data on attached fingerprint card is similar to that on file for subject of attached record; however, finger impressions are for another individual.
- Finger impressions are identical with those on file for subject of FBI No _____; however, name and description are similar to information on file of subject of FBI No _____.
A copy of each record is attached.
- Search by name only has been conducted with negative results.
- Fingerprint search has been conducted with negative results.
- Essential information omitted; name, sex, descriptive data, DOB, fingerprints, person to be notified in case of emergency.
- Submit ten finger impression fingerprint card (refer to our letter to all fingerprint contributors dated 6/17/85, copy attached).
- Fingerprint card with nonserious offense/no arrest charges.
- Fingerprint card with missing/incorrect contributor's name and number.
- Fingerprint illegible - submit another fingerprint card.
- REJ/50 - Transaction received for processing matches NFF record from your state.
- REJ/51 - SID on file different than SID on print.
- REJ/52 - SID previously established for another FNU.
- REJ/53 - SID missing for NFF participant.
- Other UNABLE TO PROCESS FINGERPRINT CARD WITH #10 FINGER ONLY.

After making appropriate changes and/or additions, please resubmit. Your cooperation is appreciated.

THE DEPARTMENT OF HEALTH
VITAL STATISTICS

BURIAL-TRANSIT PERMIT

PERMIT
NUMBER

AL A ON DECEASED	1. Full name of deceased <i>Unknown</i>		2. Date of death (month, day, and year) <i>2/22</i>		3. Death due to communicable disease YES <input type="checkbox"/> NO <input checked="" type="checkbox"/>	
	4. Sex <i>Male</i>	5. Color or race <i>White</i>	6. Age in years <i>Unknown</i>	7. Place of death (city or precinct no.) (county) (state) <i>Unknown</i>		
MANNER AND PLACE OF DISPOSAL	Method of disposal Burial <input type="checkbox"/> Removal <input checked="" type="checkbox"/>		Cremation <input type="checkbox"/> Disinterment <input type="checkbox"/>		Place of burial (name of cemetery or crematorium) (city or town) (state) removal or disposal	
	Name of funeral director <i>Albert L. Godsey</i>		License number <i>6357</i>	Business address <i>Box 618, San Augustine</i>		
Name of embalmer (if none, write none) <i>Albert L. Godsey</i>		License number <i>4823</i>	Business address <i>" " " " "</i>			
AUTHORIZA- TION TO DISPOSE OF BODY	A certificate of death having been filed as required by the laws of Texas and all laws and regulations governing the preparation and disposal of dead bodies having been complied with, permission is hereby given to dispose of the body as identified above.					
	Signature of local registrar <i>C. A. [Signature]</i>		District (city or precinct no.) (county) <i>Precinct 21 San Augustine Precinct</i>	Date <i>Jan 8-11-73</i>		
DISPOSITION OF BODY	Body was Buried <input type="checkbox"/> Cremated <input type="checkbox"/>	Date	Name of cemetery or crematory			
	Location (city or town) (county) (state)		Name of sexton or person in charge			

WILLIAM RAY LAWRENCE

SAN AUGUSTINE

- (1) AUTOPSY NOT DONE BY DR. JOE, BECAUSE HE NEVER RECEIVED BODY
- (2) KNOWN DENTAL X-RAY OF LAWRENCE BY DR. W. L. GEORGE
- (3) GOT PHOTOGRAPHS OF BODY
- (4) COMPARED X-RAY OF TEETH TO PHOTO OF DENTAL WORK
- (5) THIS COMPARTISON MATCHES

PRIOR EXHIBIT NOS.

ITEM

#81	—	DR. V.	X-RAYS OF TEETH BY DR. GEORGE
#83			PHOTO OF BILLY LAWRENCE (DEAD)
#25			POLOROID PHOTO OF BILLY LAWRENCE
#84		DR. FLANNERY	NEWS PHOTO OF BILLY LAWRENCE

WILLIAM RAY LAWRENCE

- (1) NO X-RAY EQUIPMENT

EXTERNAL XAM -

- (1) SKIN SLIPPAGE
- (2) FEATURES OF BODY WELL PRESERVED
- (3) PLASTIC SHEET AROUND BODY
- (4) CORD AROUND NECK - WITH SLIP KNOT - LIKE HANGMAN'S NOOSE
IT WAS VERY TIGHT - KNOT ON BACK 1' OF CORD HUNG DOWN
- (5) DEEP GROOVE IN NECK UNDER CORD
- (6) BLOOD (HEMORRHAGE) IN TISSUES UNDER CORD
- (7) APPEARED STRANGULATION BEFORE DEATH CHOKING WITH CORD WILL
CAUSE HEMORRHAGE
- (8) ADHESIVE TAPE AROUND WRISTS, BEHIND
- (9) ADHESIVE TAPE AROUND ANKLES
- (10) FACE RECOGNIZABLE THOUGH NOSE DECOMPOSED
- (11) TEETH PRESENT EXCEPT TWO (2) - RIGHT #1 OR # 8
1ST UPPER MOLAR & BACK WISDOM FOUND IN MOUTH - FELL OUT OF
SOCKET AFTER DEATH
SEE PG. 0763

INTERNAL XAM -

- (1) 5'8" TALL
- (2) VISUAL EXAM (DIDN'T WEIGH) 125 - 140 LBS.
- (3) 14-16 YR. OLD W/M
- (4) LIGHT TAN OR LIGHT BROWN HAIR 12" - 15" LONG
- (5) SHOW PHOTO OF LAWRENCE & DR. WILL I.D.
- (6) COMPARED DR. JOE'S X-RAYS OF TEETH TO PHOTO OF TEETH
- (7) HE HAD BEEN SUPPLIED A PHYSICAL DESCRIPTION OF BILLY -
MATCHED & HAD ALL TEETH
- (8) NO CAVITIES OR FILLINGS-TWO FRONT TEETH WERE MODERATELY
PROMINENT, LARGER THAN OTHERS; NOTCHING EFFECT OF THESE 2
TEETH - IN DESCRIPTION & BODY
- (9) BLUE EYES - DESCRIPTION & BODY
- (10) NO FILLINGS IN TEETH OF BODY EXAMINED & NO CAVITIES
- (11) DESCRIPTION HE HAD BEEN GIVEN - INCLUDED PROMINENT FRONT
TEETH & THIS MATCHED
- (12) PHOTO OF BILLY - SAME & SHOWS NOTCHING IN TEETH
- (13) NOTCHING SHOWS IN X-RAY

- (14) BASED ON VISUAL XAM - HEIGHT, COLOR EYES, COLOR & LENGTH OF HAIR, WEIGHT & PHOTOS - HIS OPINION - BILLY LAWRENCE
- (15) CAUSE OF DEATH - STRANGULATION
- (16) DID AUTOPSY - AUGUST 10, 1973 BODY DEAD APPROXIMATELY ONE MONTH

#22

DATE 8-10-73 RACE W SEX M EST. AGE _____

Comp. cases 73-3376 + 73-3377

ML# 73-3378 + 3377

TIME 10:55 LOCATION San Augustine

HEIGHT 5-8" approx WEIGHT RESIDUAL 75# EYES _____ HAIR Dark brown

HCME INVESTIGATOR _____ RETURN _____

CAN BODY BE VIEWED YES NO

POLICE AGENCY _____

CASE NUMBER _____

PRINTS TO HPD _____

PRINTS TO HCSO TO AFIS 12.10.94 NO HTT

PRINTS TO DPS 1-17-95

PRINTS TO FBI _____

MANNER 5-2-95 2180 hr 40

DOCTOR J. L. J. Leiby DPA

SCARS: _____

TATTOOS: _____

DENTAL: done

X-RAYS: AFIS SEARCH

PERSONAL EFFECTS: _____

CLOTHING: _____

DENTAL RECORD BY: _____ DATE _____

FINGERPRINTED BY: Lorint by J. Marques DATE: 4-9-90

DECEDENT'S NAME:	_____
DECEDENT'S ADDRESS:	_____
D.O.B.:	_____
PHONE #:	_____
NEXT OF KIN:	_____
ADDRESS:	_____
RELATION:	_____
PHONE #:	_____
IDENTIFIED BY:	_____
ADDRESS:	_____
PHONE #:	_____
DATE:	_____
TIME:	_____
HCME OFFICER PRESENT:	_____
HPD ID #:	_____
HCSO ID #:	_____
DPS ID #:	_____
FBI ID #:	_____